

# Anatomy of the human Pelvis

د.فلاح الخفاجي

- ❖ The pelvis : is the region of the trunk that lies below the abdomen.
- ❖ The bony pelvis is composed of four bones: the two hip bones, which form the lateral and anterior walls, and the sacrum and the coccyx, which are part of the vertebral column and form the back wall .
- ❖ The two hip bones articulate with each other anteriorly at the symphysis pubis and posteriorly with the sacrum at the sacroiliac joints.
- ❖ The pelvis is divided into two parts by the pelvic brim(pelvic inlet), which is formed by the sacral promontory (anterior and upper margin of the first sacral vertebra) behind, the iliopectineal lines (a line that runs downward and forward around the inner surface of the ileum) laterally, and the symphysis pubis (joint between bodies of pubic bones) anteriorly.
- ❖ Above the brim is the false pelvis, which forms part of the abdominal cavity. Below the brim is the true pelvis.
- ❖ The pelvic outlet is bounded posteriorly by the coccyx, laterally by the ischial tuberosities, and anteriorly by the pubic arch .
- ❖ The pelvic outlet has three wide notches.  
Anteriorly, the pubic arch is between the ischiopubic rami, and laterally are the sciatic notches.  
The sciatic notches are divided by the sacrotuberous and sacrospinous ligaments into the greater and lesser sciatic foramina .

## Structure of the Pelvic Walls

### Anterior Pelvic Wall

The anterior pelvic wall is formed by the bodies of the pubic bones, the pubic rami, and the symphysis pubis.

### Posterior Pelvic Wall

The posterior pelvic wall is formed by the sacrum and coccyx and by the piriformis muscles and their covering of parietal pelvic fascia.

### Sacrum

The sacrum consists of five rudimentary vertebrae fused together to form a single wedge-shaped bone with a forward concavity.

The sacral canal contains the anterior and posterior roots of the lumbar, sacral, and coccygeal spinal nerves; the filum terminale; and fibrofatty material.

## Coccyx

The coccyx consists of four vertebrae fused together to form a small triangular bone, which articulates at its base with the lower end of the sacrum .

## Piriformis Muscle

The piriformis muscle arises from the front of the lateral mass of the sacrum and leaves the pelvis to enter the gluteal region by passing laterally through the greater sciatic foramen . It is inserted into the upper border of the greater trochanter of the femur.

- Action: It is a lateral rotator of the femur at the hip joint.
- Nerve supply: It receives branches from the sacral plexus.

## Lateral Pelvic Wall

The lateral pelvic wall is formed by part of the hip bone below the pelvic inlet, the obturator membrane, the sacrotuberous and sacrospinous ligaments, and the obturator internus muscle and its covering fascia.

## Obturator Membrane

The obturator membrane is a fibrous sheet that almost completely closes the obturator foramen, leaving a small gap, the obturator canal, for the passage of the obturator nerve and vessels as they leave the pelvis to enter the thigh.

## Sacrotuberous Ligament

The sacrotuberous ligament is strong and extends from the lateral part of the sacrum and coccyx and the posterior inferior iliac spine to the ischial tuberosity .

## Sacrospinous Ligament

The sacrospinous ligament is strong and triangle shaped. It is attached by its base to the lateral part of the sacrum and coccyx and by its apex to the spine of the ischium .

The two ligaments convert the greater and lesser sciatic notches into foramina, the greater and lesser sciatic foramina.

## Obturator Internus Muscle

The obturator internus muscle arises from the pelvic surface of the obturator membrane and the adjoining part of the hip bone . The muscle fibers converge to a tendon, which leaves the pelvis through the lesser sciatic foramen and is inserted into the greater trochanter of the femur.

- Action: It laterally rotates the femur at the hip joint.

- Nerve supply: The nerve to the obturator internus, a branch from the sacral plexus

### Inferior Pelvic Wall, or Pelvic Floor

The floor of the pelvis supports the pelvic viscera and is formed by the pelvic diaphragm.

### Pelvic Diaphragm

The pelvic diaphragm is formed by the important levatores ani muscles and the small coccygeus muscles and their covering fasciae . It is incomplete anteriorly to allow passage of the urethra in males and the urethra and the vagina in females.

### Levator Ani Muscle

The levator ani muscle is a wide thin sheet that has a linear origin from the back of the body of the pubis, a tendinous arch formed by a thickening of the fascia covering the obturator internus, and the spine of the ischium .

Include: levator prostatae(male) or sphincter vaginae(female), puborectalis , pubococcygeus , iliococcygeus

- Action: The levatores ani muscles of the two sides form an efficient muscular sling that supports and maintains the pelvic viscera in position. They resist the rise in intrapelvic pressure during the straining and expulsive efforts of the abdominal muscles (as occurs in coughing). They also have an important sphincter action on the anorectal junction, and in the female they serve also as a sphincter of the vagina.
- Nerve supply: The perineal branch of the fourth sacral nerve(S4) and from the perineal branch of the pudendal nerve

### Coccygeus Muscle

This small triangular muscle arises from the spine of the ischium and is inserted into the lower end of the sacrum and into the coccyx .

Name of Muscle	Origin	Insertion	Nerve Supply	Action
Piriformis	Front of sacrum	Greater trochanter of femur	Sacral plexus	Lateral rotator of femur at hip joint
Obturator internus	Obturator membrane and adjoining part of hip bone	Greater trochanter of femur	Nerve to obturator internus from sacral plexus	Lateral rotator of femur at hip joint
Levator ani	Body of pubis, fascia of obturator internus, spine of ischium	Perineal body; anococcygeal body; walls of prostate, vagina, rectum, and anal canal	Fourth sacral nerve, pudendal nerve	Supports pelvic viscera, sphincter to anorectal junction and vagina
Coccygeus	Spine of ischium	Lower end of sacrum; coccyx	Fourth and fifth sacral nerve	Assists levator ani to support pelvic viscera; flexes coccyx

## Nerves of the Pelvis

### Sacral Plexus

The sacral plexus lies on the posterior pelvic wall in front of the piriformis muscle . It is formed from the anterior rami of the fourth and fifth lumbar nerves and the anterior rami of the first, second, third, and fourth sacral nerves .

### Relations

- Anteriorly: The internal iliac vessels and their branches, and the rectum
- Posteriorly: The piriformis muscle

### Branches

- Branches to the lower limb that leave the pelvis through the greater sciatic foramen :
  1. The sciatic nerve (L4 and 5; S1, 2, and 3), the largest branch of the plexus and the largest nerve in the body
  2. The superior gluteal nerve, which supplies the gluteus medius and minimus and the tensor fasciae latae muscles
  3. The inferior gluteal nerve, which supplies the gluteus maximus muscle
  4. The nerve to the quadratus femoris muscle, which also supplies the inferior gemellus muscle
  5. The nerve to the obturator internus muscle, which also supplies the superior gemellus muscle
  6. The posterior cutaneous nerve of the thigh, which supplies the skin of the buttock and the back of the thigh
- Branches to the pelvic muscles, pelvic viscera, and perineum:
  1. The pudendal nerve (S2, 3, and 4), which leaves the pelvis through the greater sciatic foramen and enters the perineum through the lesser sciatic foramen
  2. The nerves to the piriformis muscle
  3. The pelvic splanchnic nerves, which constitute the sacral part of the parasympathetic system and arise from the second, third, and fourth sacral nerves. They are distributed to the pelvic viscera.

- The perforating cutaneous nerve, which supplies the skin of the lower medial part of the buttock

### Branches of the Lumbar Plexus

- ❖ **Lumbosacral Trunk** ; Part of the anterior ramus of the fourth lumbar nerve emerges from the medial border of the psoas muscle and joins the anterior ramus of the fifth lumbar nerve to form the lumbosacral trunk.
- ❖ **Obturator Nerve**;The obturator nerve is a branch of the lumbar plexus (L2, 3, and 4), emerges from the medial border of the psoas muscle in the abdomen, and accompanies the lumbosacral trunk down into the pelvis. It crosses the front of the sacroiliac joint and runs forward on the lateral pelvic wall in the angle between the internal and external iliac vessels . On reaching the obturator canal (that is, the upper part of the obturator foramen, which is devoid of the obturator membrane), it splits into anterior and posterior divisions that pass through the canal to enter the adductor region of the thigh.
- ❖ **Autonomic Nerves**;Pelvic Part of the Sympathetic Trunk is continuous above, behind the common iliac vessels, with the abdominal part. It runs down behind the rectum on the front of the sacrum, medial to the anterior sacral foramina. The sympathetic trunk has four or five segmentally arranged ganglia.
- ❖ **Pelvic Splanchnic Nerves**; The pelvic splanchnic nerves form the parasympathetic part of the autonomic nervous system in the pelvis. The preganglionic fibers arise from the second, third, and fourth sacral nerves and synapse in ganglia in the inferior hypogastric plexus or in the walls of the viscera.

Arteries of the Pelvis
------------------------

### Common Iliac Artery

Each common iliac artery ends at the pelvic inlet in front of the sacroiliac joint by dividing into the external and internal iliac arteries

### External Iliac Artery

The external iliac artery runs along the medial border of the psoas muscle, following the pelvic brim, and gives off the inferior epigastric and deep circumflex iliac branches. It leaves the false pelvis by passing under the inguinal ligament to become the femoral artery.

### Arteries of the True Pelvis

The following arteries enter the pelvic cavity:

- Internal iliac artery
- Superior rectal artery
- Ovarian artery
- Median sacral artery

### Internal Iliac Artery

The internal iliac artery passes down into the pelvis to the upper margin of the greater sciatic foramen, where it divides into anterior and posterior divisions. The branches of these divisions supply the pelvic viscera, the perineum, the pelvic walls, and the buttocks.

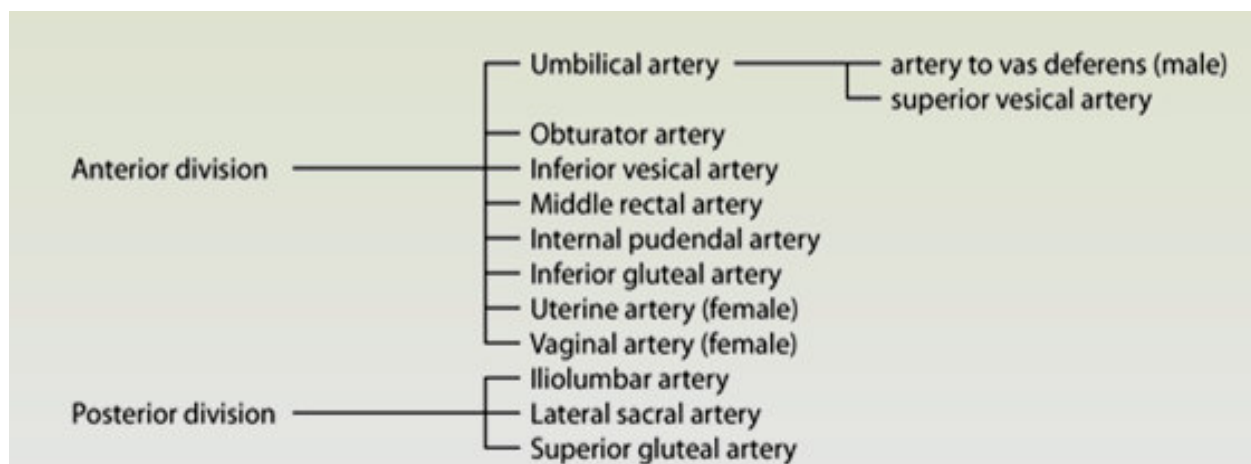
### Branches of the Anterior Division

1. Umbilical artery: From the proximal patent part of the umbilical artery arises the superior vesical artery, which supplies the upper portion of the bladder.
2. Obturator artery: This artery runs forward along the lateral wall of the pelvis with the obturator nerve and leaves the pelvis through the obturator canal.
3. Inferior vesical artery: This artery supplies the base of the bladder and the prostate and seminal vesicles in the male; it also gives off the artery to the vas deferens.
4. Middle rectal artery: Commonly, this artery arises with the inferior vesical artery. It supplies the muscle of the lower rectum and anastomoses with the superior rectal and inferior rectal arteries.
5. Internal pudendal artery: This artery leaves the pelvis through the greater sciatic foramen and enters the gluteal region below the piriformis muscle. It then enters the perineum by passing through the lesser sciatic foramen and passes forward in the pudendal canal with the pudendal nerve. Its branches supply the musculature of the anal canal and the skin and muscles of the perineum.
6. Inferior gluteal artery: This artery leaves the pelvis through the greater sciatic foramen below the piriformis muscle. It passes between the first and second or second and third sacral nerves.

7. Uterine artery: This artery runs medially on the floor of the pelvis and crosses the ureter superiorly. It passes above the lateral fornix of the vagina to reach the uterus. Here, it ascends between the layers of the broad ligament along the lateral margin of the uterus. It ends by following the uterine tube laterally, where it anastomoses with the ovarian artery. The uterine artery gives off a vaginal branch.
8. Vaginal artery: This artery usually takes the place of the inferior vesical artery present in the male. It supplies the vagina and the base of the bladder.

### Branches of the Posterior Division

1. Iliolumbar artery: This artery ascends across the pelvic inlet posterior to the external iliac vessels, psoas, and iliacus muscles.
2. Lateral sacral arteries: These arteries descend in front of the sacral plexus, giving off branches to neighboring structures .
3. Superior gluteal artery: This artery leaves the pelvis through the greater sciatic foramen above the piriformis muscle. It supplies the gluteal region.



### Superior Rectal Artery

The superior rectal artery is a direct continuation of the inferior mesenteric artery. The name changes as the latter artery crosses the common iliac artery. It supplies the mucous membrane of the rectum and the upper half of the anal canal.

### Ovarian Artery

(The testicular artery enters the inguinal canal and does not enter the pelvis.) The ovarian artery arises from the abdominal part of the aorta at the level of the first

lumbar vertebra. The artery is long and slender and passes downward and laterally behind the peritoneum. It crosses the external iliac artery at the pelvic inlet and enters the suspensory ligament of the ovary. It then passes into the broad ligament and enters the ovary by way of the mesovarium.

#### Median Sacral Artery

The median sacral artery is a small artery that arises at the bifurcation of the aorta . It descends over the anterior surface of the sacrum and coccyx.

### Veins of the Pelvis

#### External Iliac Vein

The external iliac vein begins behind the inguinal ligament as a continuation of the femoral vein. It runs along the medial side of the corresponding artery and joins the internal iliac vein to form the common iliac vein . It receives the inferior epigastric and deep circumflex iliac veins.

#### Internal Iliac Vein

The internal iliac vein begins by the joining together of tributaries that correspond to the branches of the internal iliac artery.

#### Lymphatics of the Pelvis

The lymph nodes and vessels are arranged in a chain along the main blood vessels. The nodes are named after the blood vessels with which they are associated. Thus, there are external iliac nodes, internal iliac nodes, and common iliac nodes.

### Joints of the Pelvis

#### Sacroiliac Joints

The sacroiliac joints are strong synovial joints and are formed between the auricular surfaces of the sacrum and the iliac bones. A small but limited amount of movement is possible at these joints.

#### Symphysis Pubis

The symphysis pubis is a cartilaginous joint between the two pubic bones . The articular surfaces are covered by a layer of hyaline cartilage and are connected together by a fibrocartilaginous disc. The joint is surrounded by ligaments that extend from one pubic bone to the other. Almost no movement is possible at this joint.